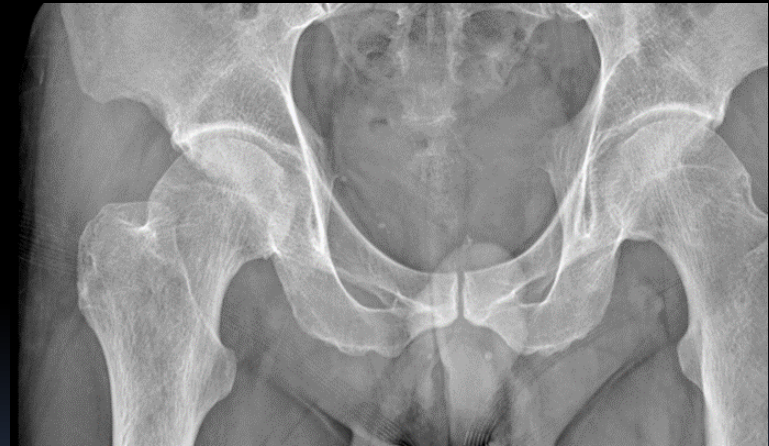

right hip trauma
pain during walking
negative radiology
one day later, pain always present

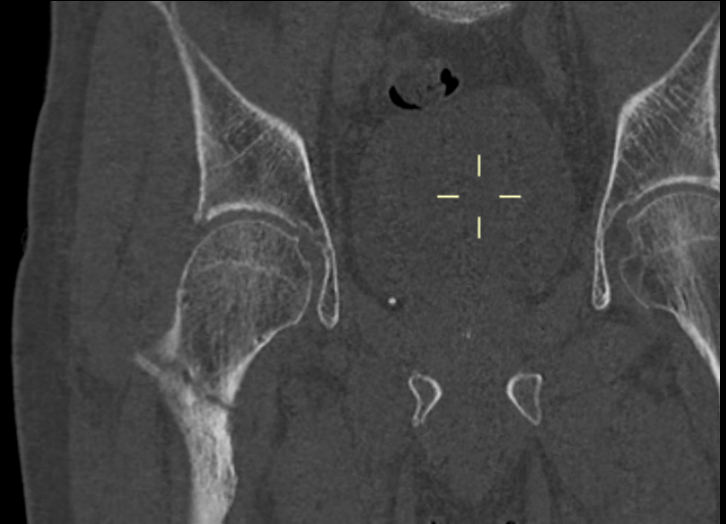


Roberto Urso MD – Orthopedic Surgeon

robertourso@robertourso.it

www.robertourso.it

performed axial tomography:
right femur fracture



“the instinct is not enough”

Roberto Urso MD – Orthopedic Surgeon
robertourso@robertourso.it www.robertourso.it